

A novel automated segmentation tool detects differential brainstem involvement in atypical parkinsonian syndromes

Martina Bocchetta¹, Juan Eugenio Iglesias², Viorica Chelban^{3,4}, Edwin Jabbari³, Ruth Lamb³, Lucy L. Russell¹, Caroline V. Greaves¹, Mollie Neason¹, David M. Cash^{1,2}, David L. Thomas^{5,6}, Jason D. Warren¹, PROSPECT consortium, John Woodside³, Henry Houlden⁴, Huw R. Morris³, Jonathan D. Rohrer¹

¹Dementia Research Centre, Department of Neurodegenerative Disease, UCL Queen Square Institute of Neurology, University College London, London, UK

²Centre for Medical Image Computing, University College London, London, UK

³Department of Movement Disorders, UCL Queen Square Institute of Neurology, University College London, London, UK

⁴Department of Neuromuscular Diseases, UCL Queen Square Institute of Neurology, University College London, London, UK

⁵Neuroradiological Academic Unit, UCL Queen Square Institute of Neurology, University College London, London, UK

⁶Leonard Wolfson Experimental Neurology Centre, UCL Queen Square Institute of Neurology, University College London, London, UK



Background

Brainstem segmentation has been useful in identifying potential imaging biomarkers for both diagnosis and progression in atypical parkinsonian disorders. However, the majority of work has been performed using manual segmentation which is time-consuming for large cohorts.

Methods

We investigated brainstem involvement in atypical parkinsonism using a novel automated segmentation tool, adapted from one used previously in Freesurfer [Iglesias *et al.*, 2015], within GIF [Cardoso *et al.*, 2015], an atlas fusion and label propagation approach. We measured the volume of the medulla, pons, superior cerebellar peduncle (SCP) and midbrain from 3T T1-weighted MRIs in 109 participants in the UCL PROSPECT and LIFTD studies: 67 patients with mean (standard deviation) age at scan of 67 (10) years and 42 age-matched controls [65 (7) years] (Figure 1). Diagnoses in the patient group were corticobasal syndrome (CBS, n=14), multiple system atrophy (MSA, n=16), progressive supranuclear palsy with a Richardson’s syndrome (PSP-RS, n=12), variant PSP [n=18: 7 PSP-CBS, 3 PSP-P, 3 PSP-F, 3 PSP-SL, 2 PSP-PGF] [Höglinger *et al.*, 2017], and 7 patients with an atypical parkinsonian syndrome (APS) not meeting criteria for a specific disorder. We performed an ANCOVA adjusted for age, gender, total intracranial volume, and scanner type.

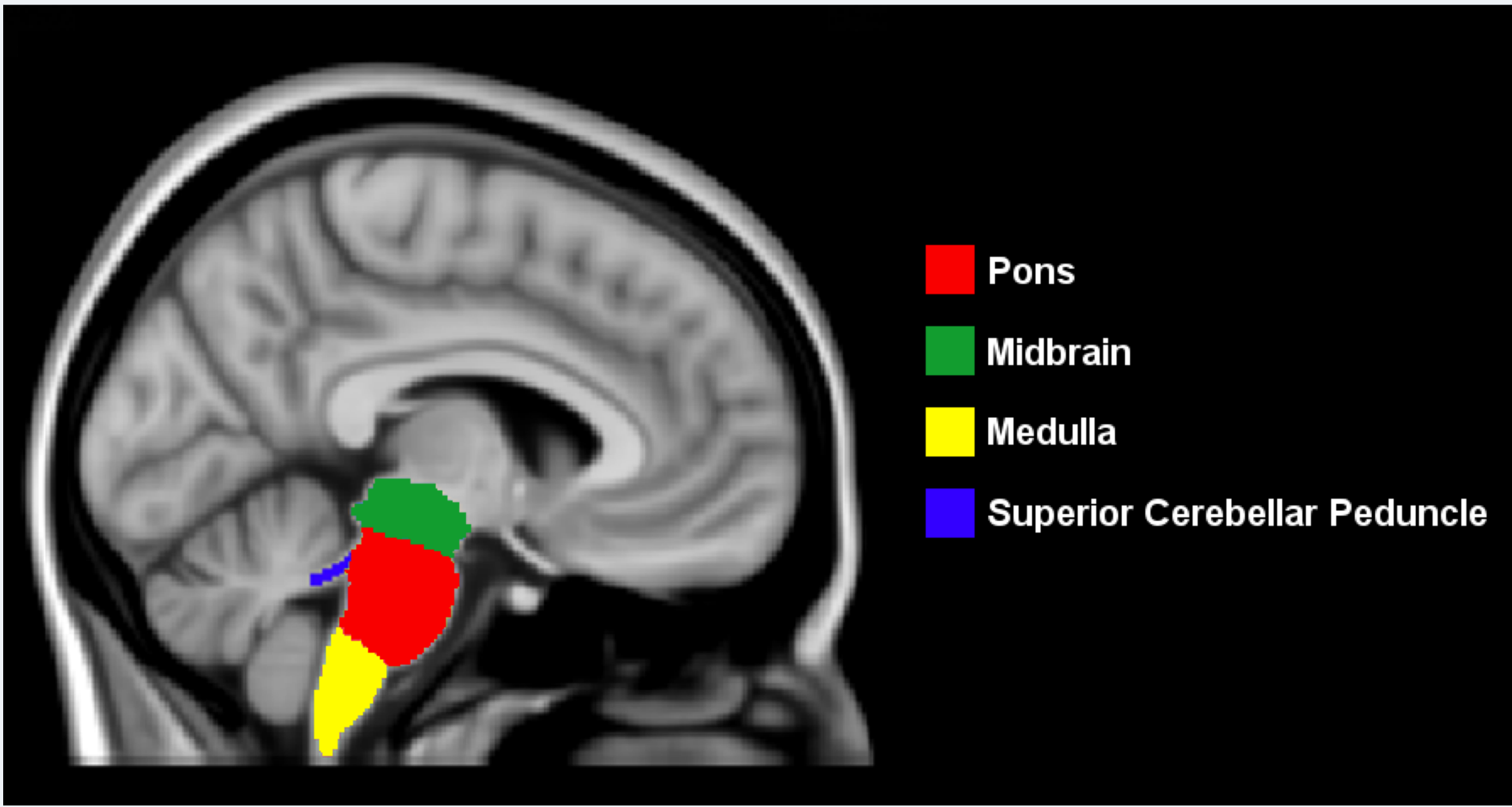


Figure 1. Example of brainstem segmentation mapped on the T1-weighted ICBM152 template.

Results

All brainstem regions were smaller in MSA (17-34% volume difference, $p<0.0005$) and in both PSP groups (18-33%, $p<0.0005$) than controls. The most affected region in MSA was the pons (34%), while the most affected regions in both PSP-RS and variant PSP were the SCP (33% and 23% respectively) and midbrain (26% and 24%). The brainstem was less affected in CBS but nonetheless the pons (14%, $p<0.0005$), midbrain (14%, $p<0.0005$) and medulla (10%, $p=0.001$) were significantly smaller than controls. The APS group did not show any significant differences (Figure 2).

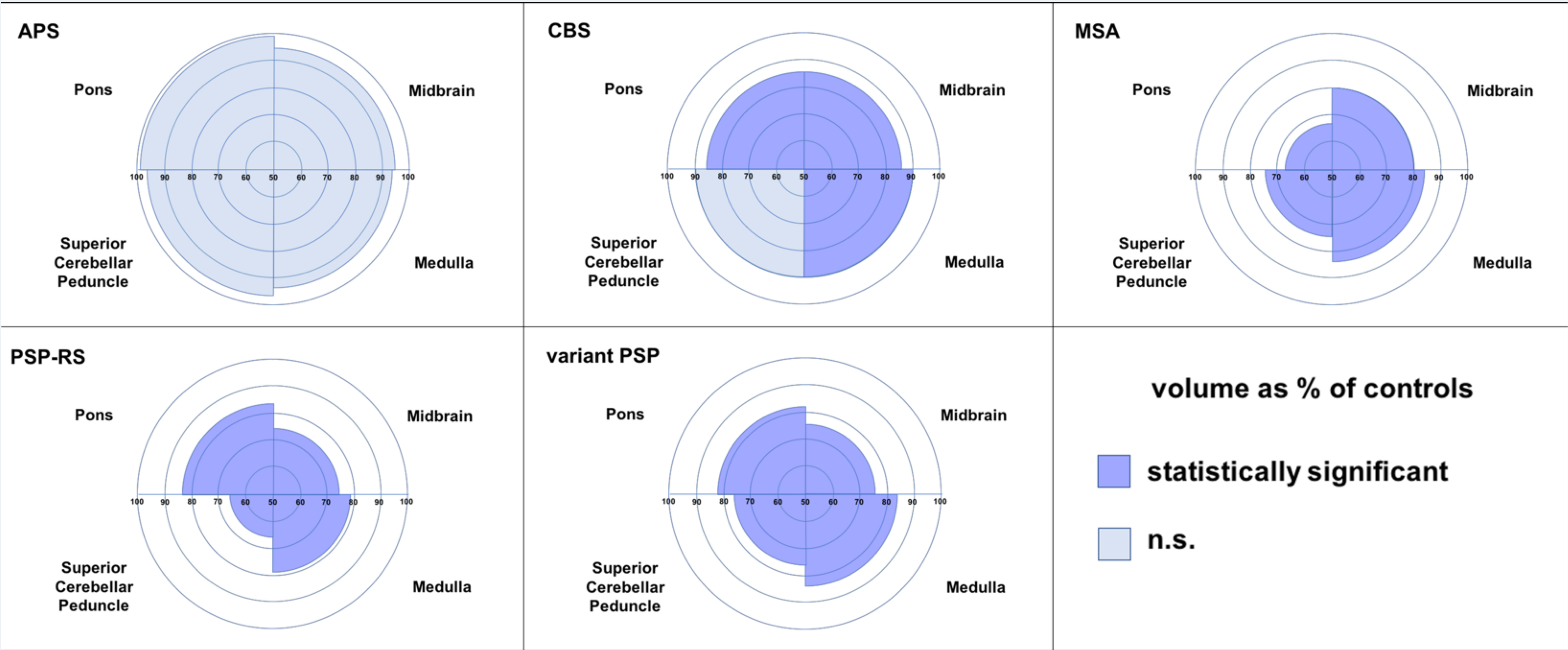


Figure 2. Percentage of volume in patients as percentage of volumes in controls.

Conclusions

Automated methods are able to accurately quantify the differential involvement of brainstem structures in atypical parkinsonism. This will be important in future trials with large patient numbers where manual segmentation is unfeasible.

Acknowledgements: The Dementia Research Centre is supported by Alzheimer's Research UK, Brain Research Trust, the Wolfson Foundation, NIHR Queen Square Dementia Biomedical Research Unit and the NIHR UCL/H Biomedical Research Centre, the MRC UK GENFI grant and the Alzheimer's Society. PROSPECT study is supported by the PSP Association and the MSA Trust. JDR is an MRC Clinician Scientist and has received funding from the NIHR Rare Diseases Translational Research Collaboration.

