

# Presymptomatic Generalized Brain Atrophy in Frontotemporal Dementia Caused by *CHMP2B* Mutation

Jonathan D. Rohrer<sup>a</sup> R. Laila Ahsan<sup>a</sup> Adrian M. Isaacs<sup>b</sup> Jorgen E. Nielsen<sup>c, d</sup>  
Leif Ostergaard<sup>e</sup> Rachael Scahill<sup>a</sup> Jason D. Warren<sup>a</sup> Martin N. Rossor<sup>a</sup>  
Nick C. Fox<sup>a</sup> Peter Johannsen<sup>c</sup> the FReJA consortium

<sup>a</sup>Dementia Research Centre and <sup>b</sup>MRC Prion Unit, Department of Neurodegenerative Disease, Institute of Neurology, University College, London, UK; <sup>c</sup>Memory Disorder Research Group, Rigshospitalet, Copenhagen University Hospital, and <sup>d</sup>ICMM, Section of Neurogenetics, The Panum Institute, University of Copenhagen, Copenhagen, and <sup>e</sup>Centre for Functionally Integrated Neuroscience, Aarhus University Hospital, Aarhus, Denmark

## Key Words

Frontotemporal lobar degeneration · *CHMP2B* mutations · Frontotemporal dementia · MRI

## Abstract

**Background/Aims:** *CHMP2B* mutations are a rare cause of familial frontotemporal dementia (FTD). The clinical syndrome is dominated by personality change and behavioural symptoms, but language, memory, calculation and praxis impairments are also seen early in the course of the disease. There are no detailed studies of brain imaging in *CHMP2B* mutation-associated FTD. This study aimed to investigate whether there were early or presymptomatic changes in this group of patients. **Methods:** Subjects comprised 16 members of a Danish family with *CHMP2B* mutation-associated FTD. Nine subjects were presymptomatic mutation carriers with a control group of 7 mutation-negative family members. Volumetric MRI brain scans were performed on all subjects at two time points, and rates of volume change were compared between the two groups. **Results:** We demonstrate that generalized atrophy occurs presymptomatically in *CHMP2B* gene mutation carriers. **Conclusions:** This finding

suggests that mutations in *CHMP2B* have widespread effects throughout the brain, leading to a neuro-anatomical signature distinct from other diseases in the frontotemporal lobar degeneration spectrum.

Copyright © 2009 S. Karger AG, Basel

## Introduction

Mutations in the *CHMP2B* gene are a rare cause of familial dementia [1]. The original descriptions of the disease linked to chromosome 3 in a large Danish family emphasized the clinical and pathological overlap with both sporadic and genetic forms of frontotemporal dementia (FTD) [2–4]. Patients generally present with changes in personality or behaviour, commonly apathy, restlessness, aggression, poor self-care and altered appetite. Behavioural change without insight remains the most prominent feature as the disease progresses. Lan-

J.D. Rohrer and R.L. Ahsan contributed equally to the paper.

guage impairment is also common, typically in the form of a dynamic aphasia (reduced spontaneous speech in the presence of preserved reading and repetition) rather than one of the canonical language syndromes within the frontotemporal lobar degeneration (FTLD) spectrum (progressive non-fluent aphasia, semantic dementia or logopenic/phonological aphasia). Neuropsychologically assessed patients may have episodic memory impairment, but this is relatively mild compared to the behavioural syndrome. Whilst these problems are attributable to frontal and/or temporal lobe dysfunction, unlike most patients with FTLD, early parietal lobe deficits, such as dyscalculia and limb apraxia, have also been described. Pathologically, *CHMP2B* mutation cases fall within the large group of FTLD cases with ubiquitin-positive inclusions; however, unlike the majority of this group, these inclusions are negative for the protein TDP-43 [5].

There are limited descriptions of brain imaging in *CHMP2B* mutation-associated FTD [4]. In these cases, atrophy appears to be generalized rather than the focal frontal and temporal lobe atrophy typically seen in FTD. This would be consistent with the additional posterior cerebral dysfunction seen clinically. However, brain imaging in previous studies was acquired a number of years into the disease, and little is known about early imaging changes in *CHMP2B* mutation-associated FTD. While presymptomatic atrophy has been demonstrated a number of years prior to symptom onset in other forms of familial FTLD [6], there are currently no studies of presymptomatic *CHMP2B* mutation carriers. Here, we describe brain imaging changes in a group of presymptomatic *CHMP2B* mutation carriers in comparison to an age-matched cohort of mutation-negative members of the same family.

## Subjects and Methods

Subjects comprised 16 members from the third and fourth generation of a Danish family with *CHMP2B* mutation-associated FTD. Nine of these were presymptomatic mutation carriers (7 males, 2 females) and a control group of 7 were known to be without the mutation (4 males, 3 females). The mean age at the time of the first scan was 54.2 years for the control group, and 55.8 years for the presymptomatic group, each predating the average age of symptomatic onset for *CHMP2B* mutation-associated FTD (57 years) by at least 1 year. There was no significant difference between the two groups in terms of age at the time of the first scan or gender. Ethical approval for the study was obtained from the County Ethics Committee in the Counties of Aarhus, Viborg-Nordjylland and Copenhagen, Denmark.

The subjects all underwent a standard clinical evaluation by an experienced neurologist used to seeing patients with *CHMP2B* mutation-associated FTD. None of the subjects had clinical symptoms or signs indicating the emergence of FTD. Furthermore, none of the subjects complained of any subjective behavioural or cognitive symptoms, and on discussion with a close family member, the participating subjects had not changed and did not show any behavioural or cognitive symptoms indicating disease onset.

Each subject underwent two volumetric brain MRI scans with a mean interval of 16 months for both groups on a GE-Excite 3T scanner at the Centre for Functionally Integrated Neuroscience, Aarhus University Hospital, Denmark. Three-dimensional  $T_1$  structural images were acquired with a three-dimensional inversion recovery fast-spoiled gradient-recalled sequence with TR/TE/TI = 6.3/2.9/750 ms, flip angle =  $14^\circ$ , in-plane resolution =  $0.94 \times 0.94 \text{ mm}^2$  ( $256 \times 256$  pixels) and slice thickness = 1.2 mm. Full head images were acquired with 126–148 axial slices using a standard head coil. Digitized images were transferred to the Dementia Research Centre, Department of Neurodegenerative Disease, Institute of Neurology, London, UK, where analysis was performed blinded to the genetic or clinical status of the subjects. The MR images were corrected for any intensity nonuniformity [7], and then delineation of the whole brain was performed. Scans were outlined using the MIDAS software package [8], a rapid semi-automated technique that involves interactive selection of thresholds, followed by a series of erosions and dilations. This yields a brain region which is separated from surrounding cerebrospinal fluid, skull and dura. The ventricles were also manually segmented, including the lateral ventricles and temporal horn of the lateral ventricles within this volume, but not the third or fourth ventricles. Additional analyses were performed by subdividing the brain into hemispheres and quadrants (anterior and posterior segments of both cerebral hemispheres). This was performed by initially transforming the scans and their associated brain regions into standard space by a 6 degrees-of-freedom registration to the Montreal Neurological Institute (MNI) template [9]. Subsequently, an intersection of the brain region and a hemispheric or quadrant subregion defined on the MNI template was generated. This provided a measure of the brain volume in the following regions: left hemisphere, right hemisphere, anterior hemi-brain, posterior hemi-brain and all four quadrants of the brain (left anterior, right anterior, left posterior and right posterior quadrants). Rates of volume change for the whole brain, ventricles, hemispheres and hemi-brain were calculated by subtracting the repeat scan measurement from the baseline measurement then expressing as a percentage of the baseline volume (except for the ventricles which are expressed as millilitres per year) and finally adjusting to an annualized rate according to the interscan interval. Anteroposterior profiles were generated for both the control group and the mutation carriers by plotting the mean area of each coronal brain slice (in standard MNI space) generated from the whole brain segmentation from anterior to posterior.

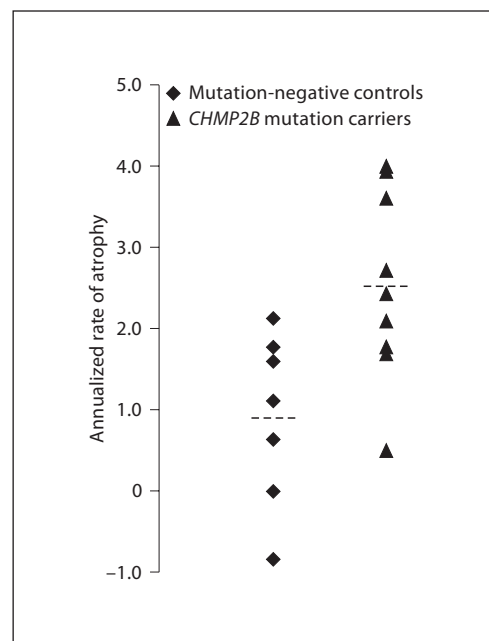
Quadrant volumes and anteroposterior profiles were also calculated in a group of 19 patients (12 males, 7 females) with pathologically confirmed FTLD (all with tau-positive pathology). This group had an average age of 54.6 years at scanning and had had symptom onset on average 6 years previously. There were no statistically significant differences between the tau-positive FTLD cases and either the *CHMP2B* carriers or healthy controls with respect to age at scan acquisition.

STATA 8 (StataCorp, College Station, Tex., USA) was used for statistical analysis. All segmentations were performed twice and the results averaged to reduce measurement error. Two-sample t tests assuming unequal variance were used to compare the rates of brain atrophy and ventricular enlargement between the groups [10].

## Results

A significantly greater mean annualized whole brain atrophy rate was found in the presymptomatic mutation carrier group relative to the healthy control group: 2.53% (standard deviation, SD 1.17) in the presymptomatic group versus 0.92% (SD 1.06) in controls ( $p < 0.05$ ) (fig. 1). Mutation carriers also had significantly greater mean rates of ventricular enlargement [1.40 ml/year (SD 1.13) in mutation carriers, 0.58 ml/year (SD 0.54) in controls,  $p < 0.05$ ] and cerebral hemisphere atrophy [right hemisphere: 2.16% (SD 1.01) in mutation carriers, 0.93% (SD 1.09) in controls,  $p < 0.05$ ; left hemisphere: 2.30% (SD 0.99) in mutation carriers, 0.72% (SD 1.42) in controls,  $p < 0.05$ ]. Rates of anterior and posterior hemi-brain atrophy were also significantly greater in the mutation carriers than in controls [anterior hemi-brain: 2.47% (SD 1.26) in mutation carriers, 0.66% (SD 1.80) in controls,  $p < 0.05$ ; posterior hemi-brain 2.73% (SD 1.73) in mutation carriers, 1.20% (SD 1.34) in controls,  $p < 0.05$ ]. For the mutation carriers, there was no significant difference between the rates of atrophy in the left and right hemispheres nor between the rates of atrophy in the anterior and posterior hemi-brains.

In order to assess cerebral asymmetry directly, the ratio of right to left hemisphere volume was measured in each subject and the mean ratios compared between the mutation and healthy control groups. The mean ratio for the repeat scan was 1.00 in both groups with a range of 0.99–1.02 for the carriers and of 0.99–1.01 for the controls, indicating no asymmetry of atrophy in the *CHMP2B* mutation cases (no significant difference between groups,  $p = 0.75$ ). In order to assess whether an anteroposterior gradient of atrophy was present, a ratio of the anterior hemi-brain volume to the posterior hemi-brain volume was calculated. The mean anteroposterior ratio was 0.76 (range 0.73–0.81, not significantly different) in both mutation carriers and controls. The mean anteroposterior ratio in the tau-positive FTL D group was 0.68 (range 0.63–0.71), significantly different from both the healthy control group ( $p < 0.05$ ) and the *CHMP2B* mutation carriers ( $p < 0.05$ ). This difference is shown graphically in the anteroposterior profiles in figure 2

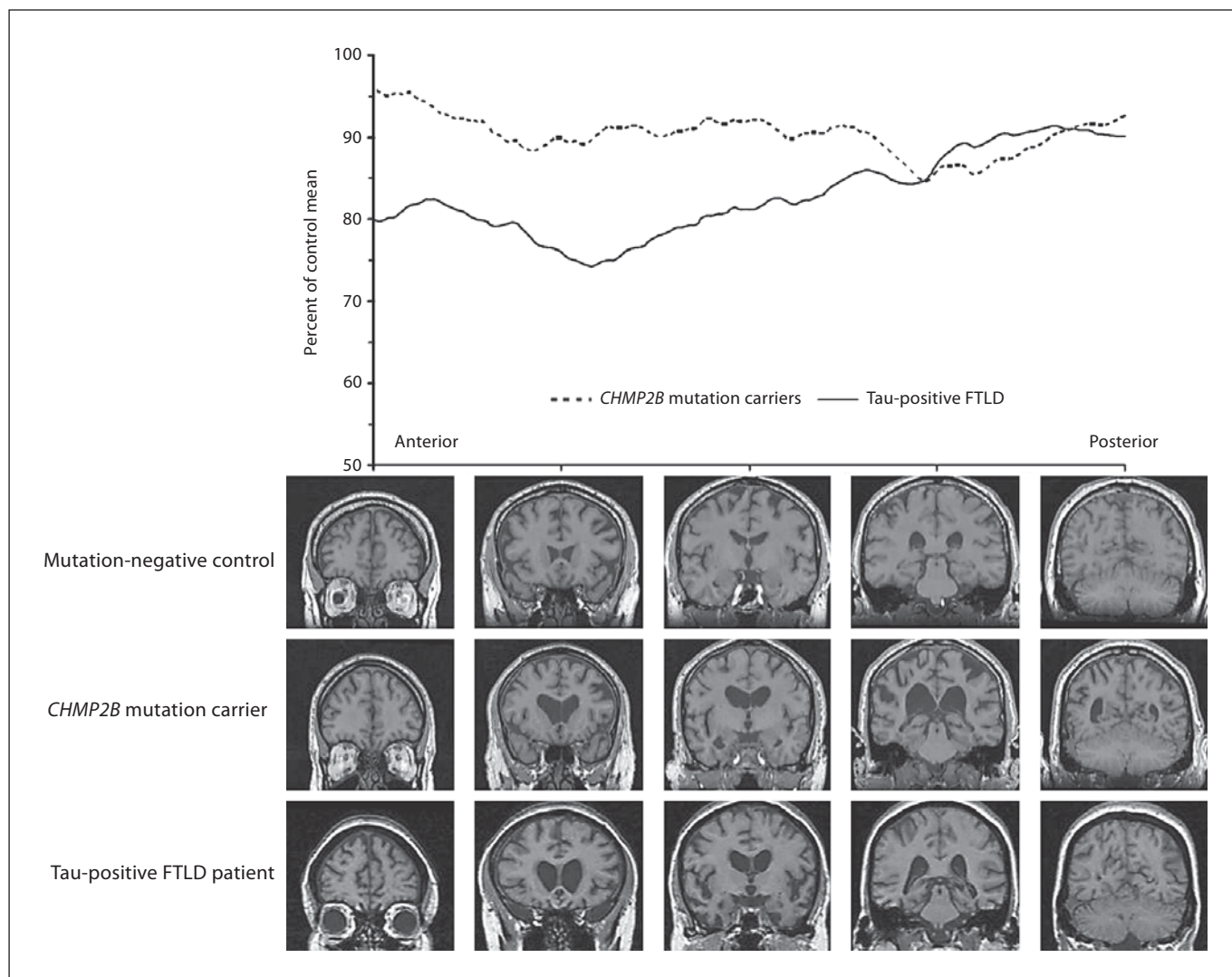


**Fig. 1.** Annualized percentage rates of whole brain atrophy in mutation-negative controls and *CHMP2B* mutation carriers (dotted line represents the mean).

which represent the mean areas at each coronal brain slice as a percentage of the control group value. Whereas a clear anteroposterior gradient is seen in the tau-positive FTL D group with greater atrophy in the frontal and temporal lobes compared to more posterior regions, there is no such gradient in the *CHMP2B* mutation carriers.

## Discussion

We have shown that brain atrophy in *CHMP2B* mutation-associated FTL D predates symptom onset and is generalized even at this presymptomatic stage. Firstly, in comparison with the control group there was evidence of cerebral atrophy in the presymptomatic mutation carriers and, secondly, there was no anteroposterior gradient of atrophy unlike the pathologically confirmed FTL D group (fig. 2), with similar rates of atrophy in both the anterior and posterior hemi-brain. This presymptomatic generalized atrophy contrasts with other diseases in the FTL D spectrum that have been shown to exhibit presymptomatic focal frontal and/or temporal lobe atrophy [6]. Posterior cerebral involvement is uncommon clinically, radiologically and pathologically in FTL D [11]. Even after symptom onset, posterior atrophy is rarely de-



**Fig. 2.** Anteroposterior profiles in *CHMP2B* mutation carriers and tau-positive FTL D patients (i.e. mean area at each brain slice as a percentage of mutation-negative control group from anterior to posterior). Representative T<sub>1</sub> coronal brain images are shown in all three groups at 5 slices (170, 145, 120, 95 and 70) from ante-

rior to posterior. This diagram shows the anteroposterior gradient characteristically seen in patients with FTL D in the tau-positive group. By comparison, the presymptomatic *CHMP2B* group does not have an anteroposterior gradient.

scribed in either sporadic FTL D or familial FTL D associated with mutations in the *MAPT* or *VCP* genes. Parietal lobe atrophy has recently been described as an early feature in patients with mutations in the progranulin gene [12, 13]. However, atrophy associated with progranulin mutations is often asymmetrical, in contrast to the cases described here in which atrophy was generalized without hemispheric predominance. This early generalized atrophy combined with the recent finding that the ubiquitin-positive, tau-negative inclusions in *CHMP2B* do not con-

tain the protein TDP-43 [5] suggests a pathogenetic distinction between *CHMP2B* mutation-associated FTD and the other genetic and sporadic forms of FTL D. One weakness of this study is the comparison of the presymptomatic group with a group of FTL D patients who already have symptomatic disease. However, comparison with presymptomatic mutation carriers of other FTL D groups is difficult because routine mutation screening and/or imaging of presymptomatic patients is uncommon. It is conceivable that the anteroposterior gradient increases as

the disease progresses, but nonetheless our results show that despite the presence of cerebral atrophy in the pre-symptomatic mutation carriers, the anterior to posterior volume ratio is not different to controls, and furthermore the rate of posterior hemi-brain atrophy is similar to the rate of anterior hemi-brain atrophy. These results suggest that a more generalized atrophic process is occurring.

The generalized atrophy mirrors *CHMP2B* gene expression, which occurs throughout the brain [1]. Thus, atrophy may reflect a general response to altered *CHMP2B* function in the brain, which is likely to affect important cellular processes [14–16]. However, further work is needed to elucidate why, despite this generalized cortical involvement, a behavioural syndrome redolent of other genetic and sporadic FTLD syndromes is the most common clinical correlate of *CHMP2B*-associated disease. We speculate that this reflects the highly distributed brain mechanisms that support executive and complex behavioural functions: a process such as *CHMP2B*-asso-

ciated disease that strikes the brain diffusely will first affect those functions most vulnerable to a random insult (or multiple insults) anywhere in the functional network.

### Acknowledgements

We would like to thank the MR technician Dora Ziedler, CFIN Aarhus University Hospital, Denmark, for her help with MR scanning. The study was supported by the Danish MRC: grant 22-04-0458. Part of this work was undertaken at UCLH/UCL which received a proportion of funding from the Department of Health's NIHR Biomedical Research Centres funding scheme. The Dementia Research Centre is an Alzheimer's Research Trust Co-ordinating Centre. This work was also funded by the Medical Research Council UK. J.D.R. is supported by a Brain Exit Scholarship. J.D.W. is supported by a Wellcome Trust Intermediate Clinical Fellowship. N.C.F. holds an MRC Senior Clinical Fellowship.

### References

- Skibinski G, Parkinson NJ, Brown JM, Chakrabarti L, Lloyd SL, Hummerich H, Nielsen JE, Hodges JR, Spillantini MG, Thuisgaard T, Brandner S, Brun A, Rossor MN, Gade A, Johannsen P, Sorensen SA, Gydesen S, Fisher EM, Collinge J: Mutations in the endosomal ESCRTIII-complex subunit *CHMP2B* in frontotemporal dementia. *Nat Genet* 2005;37:806–808.
- Brown J, Ashworth A, Gydesen S, Sorensen A, Rossor M, Hardy J, Collinge J: Familial non-specific dementia maps to chromosome 3. *Hum Mol Genet* 1995;4:1625–1628.
- Brown J: Chromosome 3-linked frontotemporal dementia. *Cell Mol Life Sci* 1998;54:925–927.
- Gydesen S, Brown JM, Brun A, Chakrabarti L, Gade A, Johannsen P, Rossor M, Thuisgaard T, Grove A, Yancopoulos D, Spillantini MG, Fisher EM, Collinge J, Sorensen SA: Chromosome 3 linked frontotemporal dementia (FTD-3). *Neurology* 2002;59:1585–1594.
- Holm IE, Englund E, Mackenzie IR, Johannsen P, Isaacs AM: A reassessment of the neuropathology of frontotemporal dementia linked to chromosome 3. *J Neuropathol Exp Neurol* 2007;66:884–891.
- Janssen JC, Schott JM, Cipolotti L, Fox NC, Scahill RI, Josephs KA, Stevens JM, Rossor MN: Mapping the onset and progression of atrophy in familial frontotemporal lobar degeneration. *J Neurol Neurosurg Psychiatry* 2005;76:162–168.
- Sled JG, Zijdenbos AP, Evans AC: A non-parametric method for automatic correction of intensity nonuniformity in MRI data. *IEEE Trans Med Imaging* 1998;17:87–97.
- Freeborough PA, Fox NC, Kitney RI: Interactive algorithms for the segmentation and quantitation of 3-D MRI brain scans. *Comput Methods Programs Biomed* 1997;53:15–25.
- Mazziotta JC, Toga AW, Evans A, Fox P, Lancaster J: A probabilistic atlas of the human brain: theory and rationale for its development. *Neuroimage* 1995;2:89–101.
- Chan D, Fox NC, Jenkins R, Scahill RI, Crum WR, Rossor MN: Rates of global and regional cerebral atrophy in AD and frontotemporal dementia. *Neurology* 2001;57:1756–1763.
- Cairns NJ, Bigio EH, Mackenzie IR, Neumann M, Lee VM, Hatanpaa KJ, White CL 3rd, Schneider JA, Grinberg LT, Halliday G, Duyckaerts C, Lowe JS, Holm IE, Tolnay M, Okamoto K, Yokoo H, Murayama S, Woulfe J, Munoz DG, Dickson DW, Ince PG, Trojanowski JQ, Mann DM; Consortium for Frontotemporal Lobar Degeneration: Neuropathologic diagnostic and nosologic criteria for frontotemporal lobar degeneration: consensus of the Consortium for Frontotemporal Lobar Degeneration. *Acta Neuropathol (Berl)* 2007;114:5–22.
- Whitwell JL, Jack CR Jr, Baker M, Rademakers R, Adamson J, Boeve BF, Knopman DS, Parisi JF, Petersen RC, Dickson DW, Hutton ML, Josephs KA: Voxel-based morphometry in frontotemporal lobar degeneration with ubiquitin-positive inclusions with and without progranulin mutations. *Arch Neurol* 2007;64:371–376.
- Rohrer JD, Warren JD, Omar R, Mead S, Beck J, Revesz T, Holton J, Stevens JM, Al-Sarraj S, Pickering-Brown S, Hardy J, Fox NC, Collinge J, Warrington EK, Rossor MN: Parietal lobe deficits are a feature of frontotemporal lobar degeneration caused by a mutation in the progranulin gene. *Arch Neurol* 2008;65:506–513.
- Filimonenko M, Stuffers S, Raiborg C, Yamamoto A, Malerød L, Fisher EM, Isaacs A, Brech A, Stenmark H, Simonsen A: Functional multivesicular bodies are required for autophagic clearance of protein aggregates associated with neurodegenerative disease. *J Cell Biol* 2007;179:485–500.
- Lee JA, Beigneux A, Ahmad ST, Young SG, Gao FB: ESCRT-III dysfunction causes autophagosome accumulation and neurodegeneration. *Curr Biol* 2007;17:1561–1567.
- van der Zee J, Urwin H, Engelborghs S, Bruyland M, Vandenberghe R, Dermaut B, De Pooter T, Peeters K, Santens P, De Deyn PP, Fisher EM, Collinge J, Isaacs AM, Van Broeckhoven C: *CHMP2B* C-truncating mutations in frontotemporal lobar degeneration are associated with an aberrant endosomal phenotype in vitro. *Hum Mol Genet* 2008;17:313–322.